

HEPATOPROTECTIVE EFFECT OF ETHANOLIC EXTRACTS OF *Sphaeranthus indicus* (Linn) ON PARACETAMOL- INDUCED LIVER TOXICITY IN RATS**K.Sundari, G. Govindaraju and B. Bharathi*¹**

P.G and Research Department of Biochemistry, PRIST University, Thanjavur, Tamilnadu, India

¹P.G and Research Department of Microbiology, PRIST University, Thanjavur, Tamilnadu, India* Corresponding author: bharathikarnan@gmail.com

ABSTRACT: Ethanolic extract of aerial parts of *Sphaeranthus indicus* L was investigated for hepatoprotective activity against paracetamol induced liver damage. Various biochemical parameters were studied to evaluate the hepatoprotective activity of ethanolic extract. In serum total bilirubin, total protein, acid phosphatase, aspartate transaminase, alanine transaminase, alkaline phosphatase, γ -Glutamyl transferase, Total Cholesterol and serum triglycerides, low density lipoprotein, high density lipoprotein were determined to assess the effect of the extract on the paracetamol induced hepatic damage. The study was also supported by histopathology of liver sections. Results of this study revealed that the markers in the animals treated with paracetamol recorded elevated concentration indicating severe hepatic damage by paracetamol, whereas the blood samples from the animals treated with ethanolic extract of roots showed significant reduction in the serum markers indicating the effect of the plant extract in restoring the normal functional ability of the hepatocytes. The dosage of extract of plant roots used was 200 & 300 mg/kg bodyweight of rat. The present study reveals that the ethanolic extract of *Sphaeranthus indicus* L 300mg/kg could afford a significant protection against paracetamol-induced hepatocellular injury.

Keywords: *Sphaeranthus indicus*, Ethanolic extract of roots, Hepatoprotective activity, Paracetamol damage.

INTRODUCTION

Herbs play a major role in the management of various liver disorders along with other system associated diseases. Liver is a key organ regulating homeostasis within the body by various functions. Liver injury caused by toxic chemicals and certain drugs has been recognized as a toxicological problem. Hepatotoxicity is one of very common ailment resulting into serious debilities ranging from severe metabolic disorders to even mortality¹. Plant derived natural products such as flavonoids, terpenoids and steroids have received considerable attention in recent years due to their diverse pharmacological properties including antioxidant and hepatoprotective activity²⁻⁴.

Sphaeranthus indicus Linn belongs to family Asteraceae. The plant is commonly known as Gorakmundi in Hindi. It is an annual spreading herb, which grows s approximately 15-30cm in heights. The plant is distributed throughout the plains and wet lands in India, Srilanka & Australia. It is used indigenously in the Indian system of medicine as an anthelmintic⁵. The plant has a wide range of medicinal value and has been used in hemicranias, jaundice, leprosy, diabetes, fever, pectoralgia, cough, gastropathy, hernia, hemorrhoids, helminthiasis, dyspepsia, skin diseases and nerve tonic^{6,7}. Pharmacological activities such as immunomodulatory³³, antimicrobial^{34,35}, antibacterial^{36,37}, anxiolytic⁷, wound healing action⁸ were reported on this plant. Phytoconstituents isolated from this plant are eudesmanolides⁹, isoflavonoids³⁸, 7-hydroxy eudesmanolides³⁹, sterol glycoside⁴⁰, essential oil (cadiene, ocimene, citral, p-methoxycinnamaldehyde, geraniol, eugenol and geranyl acetate)⁴¹, and eudesmanolides⁴². The present study was undertaken to study the possible hepatoprotective role of ethanolic extract of roots of *Sphaeranthus indicus* L.

Paracetamol (acetaminophen) is a widely used antipyretic and analgesic which produces acute liver damage if overdoses are consumed. Paracetamol is mainly metabolized in liver to excretable glucuronide and sulphate conjugates^{10, 11}. However, the hepatotoxicity of paracetamol has been attributed to the formation of toxic metabolites when a part of paracetamol is activated by hepatic cytochrome P-450¹² to a highly reactive metabolite N-acetyl- P-benzoquinone imine (NAPQI)¹³. NAPQI is initially detoxified by conjugation with reduced glutathione (GSH) to form mercapturic acid¹⁴. However, when the rate of NAPQI formation exceeds the rate of detoxification by GSH, it oxidizes tissue macromolecules such as lipid or SH group of protein and alters the homeostasis of calcium after depleting GSH. Silymarin is marketed as one of the standard hepatoprotective herbal formulation.

Plant materials

The fresh aerial parts of *Sphaeranthus indicus* L were collected during the month of February – 2009 in the Thanjavur, Tamilnadu, India. It was botanically identified and authenticated. A voucher specimen (SI-12) has been kept in our laboratory for future reference. The root was shade dried, powdered, sieved through 40 mesh and stored in a tightly closed container for future use.

Preparation of plant extract

The fresh dried powdered of *Sphaeranthus indicus* L were extracted (soxhlet) with ethanol. These extracts were condensed using rotary vacuum evaporator followed by vacuum evaporator and stored in desiccator. The powder of all the extracts was suspended in appropriate solvent systems and was subjected to further analysis.

Chemicals

Paracetamol was purchased from, CIPLA LTD., Vill. Juddikalan, Baddi, H.P. Silymarin was supplied by Panacea Biotech Ltd, New Delhi. All other chemicals and other bio chemicals used in the experiments were of analytical grade from different firms. The organic solvents were distilled before use

Animals

Wistar male Albino rats weighing between 180-200 g were used for this purpose. The animals were housed in polypropylene cages and maintained at 24 ± 2 under 12h light dark cycle and were fed *ad libitum* with standard pellet diet and had free access to water maintenance and use of animals as per the experiment was approved by the institutional Animal Ethics Committee.

Experimental designs

The experimental animals were divided into 5 groups of six rats each.

Group I: Control rats fed with standard diet.

Group II: Animals orally received paracetamol (1g kg^{-1} body weight) twice a week for 6 weeks.

Group III: Animals received 1g kg^{-1} body weight of paracetamol dissolved in glucose water orally along with 200 mg/kg body weight of ethanol extract of *Sphaeranthus indicus* L twice a week for 6 weeks.

Group IV: Animals received 1g kg^{-1} body weight of paracetamol dissolved in glucose water orally along with 300 mg/kg body weight of ethanol extract of *Sphaeranthus indicus* L twice a week for 6 weeks.

Group V: Animals received 50 mg/kg body weight of standard drug silymarin and 1g kg^{-1} body weight of paracetamol twice a week for 6 weeks and served as standard control.

Sample collection

At the end of the experimental period (45 days) the animals were sacrificed by cervical dislocation after an overnight fast. Blood sample of each group was collected separately into sterilized dry centrifuge tubes and allowed to coagulate for 30 min at 37°C .

Evaluation of effect on biochemical variables

The clear serum obtained after centrifugation was used for the estimation of serum alanine amino transferase, serum aspartate amino transferase¹⁵, alkaline phosphatase¹⁶, gamma-glutamyl transferase¹⁷, acid phosphatase¹⁸, serum protein¹⁹, serum bilirubin²⁰, cholesterol²¹ and triglyceride²². LDL, HDL⁴³

Histopathology study

Liver is dissected out and the liver samples were excised from the experimental animals of each group and washed with the normal saline. Initially the materials were fixed in 10% buffered neutral formalin and then with bovine solution. They were processed for paraffin embedding following the microtome technique. The sections were taken at 5μ thickness processed in alcohol-xylene series and were stained with alumhaematoxylin and eosin. The sections were examined microscopically for the evaluation of histopathological changes.

Statistical Analysis

The values were expressed as mean \pm SEM. Statistical analysis was performed by one way analysis of variance (ANOVA) followed by Dunnett's test was carried out and $p < 0.001$ was considered as significant.

RESULTS

Effect of ethanolic extract of *Sphaeranthus indicus* L on paracetamol induced liver injury in rats with reference to biochemical changes in serum are given in Table 1 and 2.

Table 1: The effects of *Sphaeranthus indicus L* on biomarkers of hepatic damage

Group	SGPT (IU/L)	SGOT (IU/L)	ALP (IU/L)	ACP (IU/L)	GGTP (IU/L)	Total Protein (gm/dl)	Total Bilirubin (mg/dl)
Control	76.72 ± 3.36	70.48 ± 2.36	256.42 ± 4.91	10.77 ± 0.44	87.0 ± 1.2	9.62 ± 0.36	1.60 ± 0.14
Paracetamol	343.83 ± 5.64	297.47 ± 3.16	541.73 ± 4.51	32.73 ± 0.84	129.6 ± 2.7	3.87 ± 0.21	6.20 ± 0.63
EESI 200mg/kg + APAP	173.69 ± 3.39*	161.33 ± 3.98*	338.47 ± 5.17*	26.42 ± 3.97*	85.00 ± 2.3*	6.97 ± 0.06*	2.95 ± 0.35*
EESI 300mg/kg + APAP	145.42 ± 3.21**	125.18 ± 2.33**	286.37 ± 6.37**	26.42 ± 0.60**	60.00 ± 1.23**	8.78 ± 0.22**	2.18 ± 0.15**
Silymarin 50mg/kg + APAP	112.25 ± 3.19	104.12 ± 2.68	276.45 ± 5.22	12.10 ± 0.20	55.3 ± 1.78	9.13 ± 0.26	1.97 ± 0.22

All values are in Mean ± SEM, P<0.001* significant, P<0.001** more significant Vs Control, N=6.

Table 2: The effects of *Sphaeranthus indicus L* on lipid profiles

Group	Total Cholesterol (mg/dl)	Triglycerides (mg/dl)	LDL - Cholesterol (mg/dl)	HDL - Cholesterol (mg/dl)
Control	93.60 ± 5.67	63.40 ± 4.46	25.33 ± 2.52	63.40 ± 4.46
Paracetamol	123.67 ± 5.11	89.00 ± 6.00	64.60 ± 3.28	25.60 ± 3.67
EESI 200mg/kg + APAP	95.00 ± 4.27*	50.40 ± 3.10*	38.00 ± 2.12*	35.20 ± 3.12*
EESI 300mg/kg + APAP	61.00 ± 4.36**	40.40 ± 4.31**	28.60 ± 2.22**	58.21 ± 3.12**
Silymarin 50mg/kg + APAP	58.12 ± 2.21	45.36 ± 2.11	25.22 ± 1.52	63.30 ± 4.00

All values are in Mean ± SEM, P<0.001* significant, P<0.001** more significant Vs Control, N=6.

Histological profile of animals is depicted in Figure a,b,c,d,e. At the end of 45 days treatment blood samples of paracetamol treated animals showed significant increase in the levels of total bilirubin, alanine amino transferase, aspartate amino transferase, alkaline phosphatase, acid phosphatase, γ -glutamyl transferase, cholesterol and triglyceride, LDL, HDL compared to the normal control group, but the total protein level decreased reflecting the liver injury caused by paracetamol; whereas blood samples from the animals treated with ethanolic extract of *Sphaeranthus indicus L* at the dose of 200 and 300 mg/kg body weight showed significant decrease in the levels of serum markers and significant increase in the total protein to the near normal value which are comparable to the values registered in the standard drug treated group of animals, indicating the protection of hepatic cells against paracetamol damage

DISCUSSION

Liver is largest organ and it is target for toxicity because of its role in clearing and metabolizing chemicals through the process called detoxification²³. Drug induced liver disorders occurred frequently can be life threatening and mimic all forms of liver diseases²⁴. Paracetamol being a drug capable of causing liver disorders if overdoses are consumed. The covalent binding of N-acetyl-Pbenzoquinoneimine, an oxidation product of paracetamol, to sulphhydryl groups of protein resulting in cell necrosis and lipid peroxidation induced by decrease in glutathione in the liver as the cause of hepatotoxicity have been reported earlier^{25, 26}.

Table 1 represents the changes in the activities of aspartate transaminase, alanine transaminase, alkaline phosphatase, acid phosphatase, γ -glutamyl transferase. In the assessment of liver damage by paracetamol the determination of enzyme levels such as aspartate transaminase and alanine transaminase is largely used. Elevated levels of serum enzymes are indicative of cellular leakage and loss of functional integrity of cell membrane in liver²⁷. Hepatocellular necrosis leads to high level of serum markers in the blood, among these, aspartate transaminase, alanine transaminase represents 90% of total enzyme and high level of alanine transaminase in the blood is better index of liver injury, but the elevated levels of enzymes are decreased to near normal levels after 45 days treatment of *Sphaeranthus indicus L* indicates that it offered protection by preserving the structural integrity of the hepatocellular membrane against paracetamol.

Alkaline phosphatase concentration is related to the functioning of hepatocytes, high level of alkaline phosphatase in the blood serum is related to the increased synthesis of it by cells lining bile canaliculi usually in response to cholestasis and increased biliary pressure^{28,29}. Increased level was obtained after paracetamol administration and it was brought to near normal level by *Sphaeranthus indicus L* treatment.

γ -glutamyl transferase is a microsomal enzyme, which is widely distributed in tissue including liver. The activity of serum γ -glutamyl transferase is generally elevated as a result of liver disease, since γ -glutamyl transferase is a hepatic microsomal enzyme. Serum γ -glutamyl transferase is most useful in the diagnosis of liver diseases. Changes in γ -glutamyl transferase is parallel to those of amino transferases. The acute damage caused by paracetamol increased the γ -glutamyl transferase level but the same attains the normal after *Sphaeranthus indicus L* treatment due to its antioxidant activity.

Chronic administration of paracetamol produced a marked elevation of the serum levels of enzymes in treated animals when compared with that of the control group. Treatment with *Sphaeranthus indicus* at a dose of 300 mg/kg significantly reduced the elevated levels of those enzymes. Treatment with *Sphaeranthus indicus L* decreased the serum levels of aspartate transaminase, alanine transaminase towards the respective normal value that is an indication of stabilization of plasma membrane as well as repair of hepatic tissue damage caused by paracetamol. The above changes can be considered as an expression of the functional improvement of hepatocytes, which may be caused by an accelerated regeneration of parenchymal cells. Effective control of alkaline phosphatase, acid phosphatase, γ -glutamyl transferase levels points towards an early improvement in the secretory mechanism of the hepatic cell.

Protein metabolism is a major project of liver and a healthy functioning liver is required for the synthesis of the serum proteins except for the γ globulins. Hypoproteinemia is a feature of liver damage due to significant fall in protein synthesis. Albumin is decreased in chronic liver disease and is generally accompanied by an increase in the β and γ globulins as a result of production of IgG and IgM³⁰. Hypoproteinemia was observed after paracetamol ingestion but the trend turns towards normal after *Sphaeranthus indicus L* treatment.

Serum bilirubin is one of the most sensitive tests employed in the diagnosis of hepatic diseases. Hyperbilirubinemia was observed due to excessive heme destruction and blockage of biliary tract. As a result of blockage of the biliary tract there is a mass inhibition of the conjugation reaction and release of unconjugated bilirubin from damaged and dead hepatocytes³¹. Administration of *Sphaeranthus indicus L* decreased the level of bilirubin and increased the level of protein suggesting that it offered protection.

Paracetamol seems to cause impairment in lipoprotein metabolism³² and also alterations in cholesterol metabolism. The levels of cholesterol, triglyceride, and LDL were significantly increased in paracetamol treated rats, when compared to control, silymarin and *Sphaeranthus indicus L* treated rats (Table.2). Elevation of triglycerides level during paracetamol intoxication could be due to increased availability of free fatty acids, decreased hepatic release of lipoprotein and increased esterification of free fatty acids. Administration of *Sphaeranthus indicus L* significantly decreased serum lipid profile in paracetamol toxicity induced rats because of its hypolipidemic effects. *Sphaeranthus indicus L* supplementation enhanced esterification effect through hepatoprotective property by inhibiting the free radicals effect on liver cells.

Histopathological observations

The histopathological profile of the rat of normal control in group 1 showed normal cellular architecture with distinct hepatic cells, sinusoidal spaces and central vein (Fig a). In the liver section of the rats intoxicated with Paracetamol in group 2, there is a disarrangement and degeneration of normal hepatic cells with intense centrilobular necrosis, sinusoidal haemorrhages and dilatations. There was chronic inflammatory cell infiltrate in portal tracts (Fig b). The liver section of the rats treated with ethanol extract of *Sphaeranthus indicus* 200mg/kg in group 3 and Silymarin in group 5 shows less vacuole formation reduced sinusoidal dilatations, less disarrangement and degenerations of hepatocytes indicating marked regenerative activity (Fig c, e). In rats treated with higher dose of extract i.e 300mg/kg body weight p.o., the liver appeared normal (fig.d).

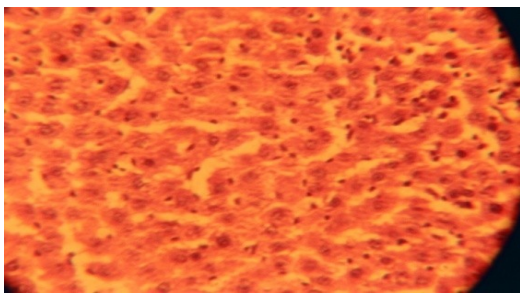


Fig. a..Histology of normal liver tissue

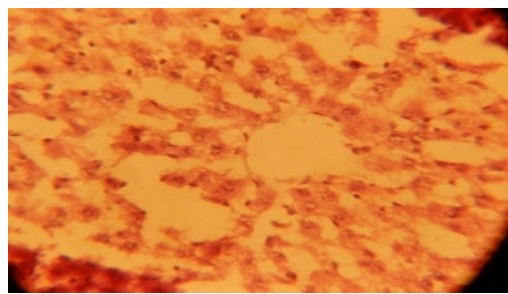


Fig.b. Histology of paracetamol induced liver Damage.

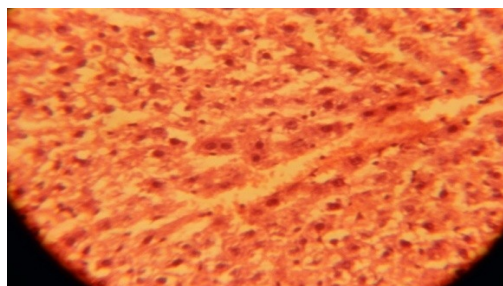


Fig.c.Histology of liver tissue treated with EESI 200mg/kg.

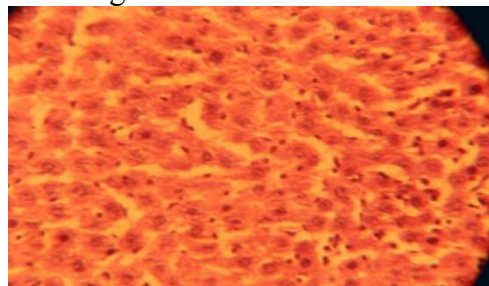


Fig.d.Histology of liver tissue treated with EESI 300mg/kg.

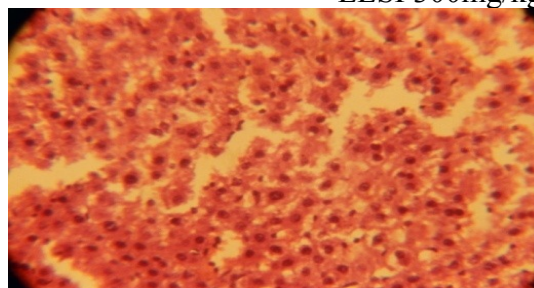


Fig.e.Histology of liver tissue treated with silymarin 50mg/kg

CONCLUSION

In conclusion, the results of the present study suggest that *Sphaeranthus indicus* has a potent hepatoprotective action upon paracetamol- induced liver toxicity in rats. The hepatoprotective effect of *Sphaeranthus indicus* can be correlated directly with its ability to reduce activity of serum enzymes. The findings of this study suggest that *S.indicus* can be used as a safe, cheap and effective alternative chemopreventive and protective agent in the management of liver diseases.

REFERENCES

1. Patel RK, Patel MM, Patel MP, Kanzaria NR, Vaghela KR, Patel NJ. Hepatoprotective activity of *Moringa oleifera* Lam. Fruit on isolated rat hepatocytes. *Phcog mag* 2008;4:118-23.
2. DeFeuids FV, Papadopoulos V, Drieu K. Ginko biloba extracts and cancer a research area in its infancy. *Fundam Clin Pharamacol* 2003;17:405-17.
3. Banskota AH, Tezuka Y, Adnyana IK, Xiong Q, Hase K, Tran KQ, et al. Hepatoprotective effect of *Commbratum quadrangulare* and its constituents. *Biol Pharm Bull* 2000;23:456-60.
4. Takeoka GR, Dao LT. Antioxidant constituent of almond (*Prunus dulcis* (Mill.) D.A.Webb) hulls. *J Agri Food Chem* 2003;51:496-501

5. G. Wart, A dictionary of economic products of india, 1971.
6. R. N. Chopra, S. L. Nayar, and J. C. Chopra, Glossary of Indian Medicinal Plants, Council of Scientific and Industrial
7. Research, New Delhi, India, 1956.
8. S. Ambavade, N. Mhetre, V. Tate, and S. Bodhankar, "Pharmacological evaluation of the extracts of *Sphaeranthus indicus* flowers on anxiolytic activity in mice," *Indian Journal of Pharmacology*, vol. 38, no. 4, pp. 254–259, 2006.
9. F. Sadaf, R. Saleem, M. Ahmed, S. I. Ahmad, and Navaidul-Zafar, "Healing potential of cream containing extract of
10. *Sphaeranthus indicus* on dermal wounds in Guinea pigs," *Journal of Ethnopharmacology*, vol. 107, no. 2, pp. 161–163, 2006.
11. P. P. Pujar, D. D. Sawaikar, S. R. Rojatkar, and B. A. Nagasampagi, "Eudesmanoids from *Sphaeranthus indicus*,"
12. *Fitoterapia*, vol. 71, no. 3, pp. 264–268, 2000.
13. Jollow DJ, Thorgeirsson SS, Potter WZ, Hashimoto M, Mitchell JR. Acetaminophen induced hepatic necrosis VI. Metabolic disposition of toxic and non-toxic doses of acetaminophen. *Pharmacology* 1974;12:251-71.
14. Wong LT, Whitehouse LW, Solemonraj G, Paul CJ. Pathways of Acetaminophen conjugate in the mouse. *Toxicity Lett* 1981;9:145-51.
15. Savides MC, Oehne FW. Acetaminophen and its toxicity. *J App Toxicol* 1983;3:95-111.
16. Vermeulen NPE, Bessems JGM., Van de Streat R. Molecular aspects of paracetamol-induced hepatotoxicity and its mechanism based prevention. *Drug Metab Rev* 1992;24:367-407.
17. Moore M, Thor H, Moore G, Nelson S, Moldeus P, Correnius S. The toxicity of acetaminophen and N-acetyl Pbenzoquinoneimine in isolated hepatocytes is associated with thio depletion and increased cytosolic Ca²⁺. *J Biol Chem* 1985;260:13035-40.
18. Reitzman S, Frankel S. A Colorimeter method for the determination of serum glutamic oxalo acetic acid, glutamic pyruvate transaminase. *Am J Clin Pathol* 1957;28:56-63.
19. King EJ, Armstrong AR. Determination of serum and bile phosphatase activity. *Canad Med Assoc J* 1934;31:56-63.
20. Rosalki SB, Rav D. Serum gamma – glutamyl transpeptidase activity in alcoholism. *Clin Chem Aceta* 1972;39:41-7.
21. King J. The hydrolase and alkaline phosphatase. In: practical clinical enzymology. London: Nostrand Co. Ltd; 1965. p. 191.
22. Lowry OH, Rosebrough NJ, Farr AL, Randall. R.J. Protein measurement with Folin's Phenol reagent. *J Biol Chem* 1951;193:265-75.
23. Malloy HT, Evelyn EA. The determination of bilirubin with photoelectric calorimeter. *J Biol Chem* 1937;119:481-5.
24. Parekh AC, Jung DH. Cholesterol determination with ferric acetate-uranium acetate and sulfuric acid-ferrous sulphate reagents. *Anal Chem* 1970;42:1423-7.
25. Gupta AA, Siddiqui IR, Singh J. A new anthraquinone glycoside from the roots of *Plumbago zeylanica*. *Indian J Chem* 2000;39:796-8.
26. Larrey D. Drug induced liver disease. *J Hepatol* 2003;32:77-88.
27. Watkins PB, Seef LB. Drug induced liver injury: Summary of a single topic research committee. *Hepatology* 2006;43:618-31.
28. Handa SS, Sharma A. Hepatoprotective activity of andrographolide from *Andrographis paniculata* against CCl₄. *Ind J Med Res (B)* 1990;92:276-83.
29. Jollow DJ, Mitchell JR, Potter WZ, Davis DC, Gillette JR, Brodie BB. Acetaminophen induced hepatic necrosis: (II) Role of covalent binding in vivo. *J Pharmacol Exp Ther* 1973;187:195-202.

30. Drotman RB, Lawhorn GT. Serum enzymes are indicators of chemical induced liver damage. *Drum Chem Toxicol* 1978;1:163-71.
31. Gaw A, Cowan RA, O'Reilly DSJ, Stewart, MJ Shepherd J. *Clinical biochemistry – an illustrated color text*. 1st ed. New York: Churchill Livingstone; 1999. p. 51-3.
32. Kim KA, Lee WK, Kim JK, Seo MS, Lim D, Lee KH et al. Mechanism of refractory ceramic fibre- and rock wool-induced cytotoxicity in alveolar macrophages. *Arch Occup Environ Health* 2001;74:9-15.
33. Kaplan LA, Pesce AJ. *Clinical chemistry*. 3rd ed. St. Louis, MO: Mosby; 1996. p. 517.
34. Wolf A, Diez-Fernandez C, Trendelenburg CF, Prieto P, Hary S, Trammer WE. Paracetamol induced oxidative stress in rat hepatocytes. *J Pharm Exp Ther* 1997;280:1328-34.
35. Kobashigania JA, Kasiska BL. Hyperlipidemia in solid organ transplantation. *Transplantation* 1997;63:333-8.
36. A.R. Bafna and S. H. Mishra, "Immunomodulatory activity of methanol extract of flower-heads of *Sphaeranthus indicus* Linn," *Ars Pharmaceutica*, vol. 45, no. 3, pp. 281–291, 2004.
37. K. S. Dubey, A. H. Ansari, and M. Hardaha, "Antimicrobial activity of the extract of *Sphaeranthus indicus*," *Asian Journal of Chemistry*, vol. 12, no. 2, pp. 577–578, 2000.
38. S. K. Singh, K. M. Saroj, V. H. Tripathi, A. K. Singh, and R. H. Singh, "An antimicrobial principle from *Sphaeranthus indicus* L. (family compositae)," *International Journal of Crude Drug Research*, vol. 26, no. 4, pp. 235–239, 1988.
39. R. T. Mahajan, G. S. Chaudhari, and M. Z. Chopda, "Screening of some indigenous plants for their possible antibacterial activity," *Environmental Bulletin*, vol. 15, pp. 61–62, 1999.
40. S. C. Garg and H. L. Kasera, "In vitro antibacterial activity of the essential oil of *Sphaeranthus indicus* L.," *Fitoterapia*, vol. 54, pp. 37–39, 1983.
41. R. N. Yadava and S. Kumar, "A novel isoflavone glycoside from the leaves of *Sphaeranthus indicus*," *Fitoterapia*, vol. 70, no. 2, pp. 127–129, 1999.
42. S. R. Rojatkar and B. A. Nagasampagi, "7- Hydroxyeudesmanolides from *Sphaeranthus indicus*," *Phytochemistry*, vol. 31, no. 9, pp. 3270–3271, 1992.
44. S. K. Singh, V. J. Tripathi, and R. H. Sing, " β -D-Glucoside of 24(s)24-ethylcholesta-5,22-dien-3- β -ol from *Sphaeranthus indicus* L.," *Indian Drugs*, vol. 26, pp. 317–318, 1988.
45. V. Lodha, "Chemical analysis of the essential oil of *Sphaeranthus indicus*-An ayurvedic plant of India," *Indian Perfumer*, vol. 47, pp. 29–30, 2003.
46. M. S. Shekhani, P. M. Shah, K.M. Khan, and Atta-ur-Rahman, "New eudesmanolides from *Sphaeranthus indicus*," *Journal of Natural Products (Lloydia)*, vol. 54, no. 3, pp. 882–885, 1991.
47. Friedewald, W.T., R.I. Levy and D.S. Fredrickson, 1972. Estimation of the concentration of LDL cholesterol in plasma, without use of the preparative ultracentrifuge. *Clin. Chem.*, 18: 499-502.